

VIDEOS IN CLINICAL MEDICINE

Nasogastric Intubation

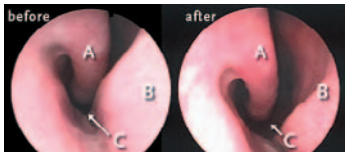
Todd W. Thomsen, M.D., Robert W. Shaffer, M.D., and Gary S. Setnik, M.D.

INDICATIONS*Decompression of the Gastrointestinal Tract*

From the Department of Emergency Medicine, Mount Auburn Hospital, Cambridge, Mass.; and the Division of Emergency Medicine, Harvard Medical School, Boston. Address reprint requests to Dr. Thomsen at the Department of Emergency Medicine, Mount Auburn Hospital, 330 Mount Auburn St., Cambridge, MA 02238, or at tthomsen@mah.harvard.edu.

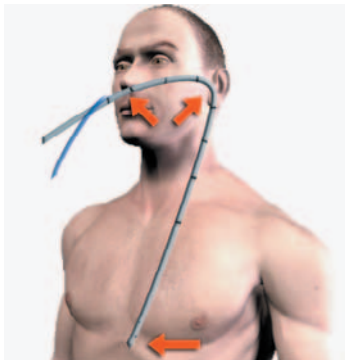
N Engl J Med 2006;354:e16.

Copyright © 2006 Massachusetts Medical Society.



The nasal cavity before and after treatment with oxymetazoline

Pictured are the inferior turbinate (A), the nasal septum (B), and the nasal passageway (C).



Measuring the depth of insertion

Nasogastric intubation and suction are required to remove enteric secretions and swallowed air in patients with obstructions of the small bowel or gastric outlet. Nasogastric intubation may also provide symptomatic relief for patients with severe pancreatitis and associated ileus; however, routine placement of nasogastric tubes in patients with mild or moderate symptoms is not indicated, since this may result in prolonged nausea and vomiting and extended hospitalization.¹⁻³

Nasogastric (or orogastric) intubation and suction may be beneficial in patients undergoing mechanical ventilation with the use of an endotracheal tube in order to prevent aspiration of gastric contents.

Administration of Oral Agents

Oral agents (e.g., activated charcoal or radiographic contrast material) may be administered through a nasogastric tube in patients unable to tolerate fluids delivered orally.

Gastrointestinal Hemorrhage

Nasogastric intubation and suctioning may be performed in patients with severe upper gastrointestinal bleeding in order to provide symptomatic relief and to facilitate endoscopic visualization of the gastric and duodenal mucosa. In the absence of frank bloody return, examination of nasogastric aspirates has a suboptimal sensitivity and specificity and cannot be relied on to confirm or rule out active hemorrhage in patients with a history of hematemesis or melena.^{4,5}

CONTRAINDICATIONS*Maxillofacial Trauma*

Nasogastric intubation should be avoided in patients with substantial maxillofacial trauma in order to avoid passage of the tube into the cranial vault through a potentially disrupted cribriform plate.⁶

Esophageal Abnormalities

The risk of esophageal perforation is high among patients with a recent history of ingestion of caustic substances and those in whom esophageal strictures or diverticula are present.⁷ In most cases, nasogastric intubation may be performed safely in patients with esophageal varices.⁸

Altered Mental Status and Impaired Defenses

Nasogastric intubation may precipitate vomiting and thus should be avoided in patients with altered mental status or impaired airway defenses. In such patients, endotracheal intubation should precede nasogastric intubation if the procedure is indicated.

PREPARATION

Explain the procedure to the patient, and obtain informed consent. To choose the appropriate side of the nose for insertion, first assess the patency and symmetry of

the nares by asking the patient to inhale alternately through each nostril, noting which side provides superior flow. An otoscope may be used to examine the passageway directly to identify septal deviation or other anatomical restrictions. Pretreatment of the nasal passageways with oxymetazoline or phenylephrine will constrict the vessels of the nasal mucosa, allow easier insertion of the tube, and reduce the risk of epistaxis. The nasal mucosa can be anesthetized topically with the use of 4 percent lidocaine delivered with an atomizer or with viscous lidocaine injected directly into the nasal canal. Topical anesthesia should also be applied to the posterior oropharynx with atomized 4 percent lidocaine or benzocaine spray. Alternatively, 4 percent lidocaine delivered with a nebulizer provides excellent anesthesia of both the nasal and the oral mucosa.

Estimate the proper depth that the tube should be inserted by measuring the distance from the xiphoid process to the angle of the mandible and then to the nostril. Note the corresponding distance mark on the tube.

TUBE INSERTION

Gather your equipment. You will need gloves, a protective gown, and a face shield; a nasogastric tube; lubricant (viscous lidocaine or surgical jelly); vasoconstrictor spray (e.g., oxymetazoline); a topical anesthetic; atomized 4 percent lidocaine; a glass of water and a straw; an emesis basin; absorbent towels or pads; a catheter-tip (Toomey) syringe; a stethoscope; adhesive tape; and a suction unit. Position the patient so that he or she is sitting upright in the “sniffing” position (neck flexed and head extended). Lubricate the distal end of the nasogastric tube and insert it into the nasal cavity, slowly passing it posteriorly along the floor of the nasal canal. Continue to advance the tube slowly into the posterior oropharynx. The patient may gag or you may feel resistance as the tube nears the laryngeal apparatus. If so, temporarily halt the advancement and instruct the patient to sip water through the straw. Coordinate further advancement of the tube with instructions to the patient to swallow. As the patient swallows, the epiglottis will cover the trachea and prevent inadvertent placement of the tube in the trachea. Once the tube is past the larynx, guide it rapidly to the predetermined depth.

CONFIRMATION OF TUBE PLACEMENT

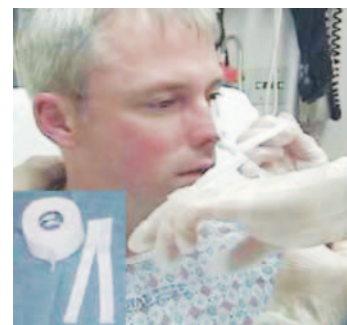If the patient is unable to talk or is in respiratory distress or if respirations can be heard through the nasogastric tube, tracheal intubation has probably occurred, and the tube should be immediately removed. Proper gastric placement is suggested (though not unequivocally confirmed) by auscultating borborygmus over the epigastrium as air is injected into the tube with the catheter-tip syringe. If there is any question with regard to proper placement, or if agents such as activated charcoal are to be instilled through the tube, a chest radiograph should be obtained to confirm placement. Visualization of the descent of the tube below the diaphragm provides such confirmation.

SECURING THE NASOGASTRIC TUBE AND INITIATING SUCTIONING

To secure the tube, cut a 7-cm length of 1-in.-wide adhesive tape and tear it halfway down its vertical length. Apply the wide end to the patient’s nose, and wrap the two “tails” around the tube. At this point, the tube can be connected to the suctioning equipment. Intermittent, low suction should be used for the majority of patients.

COMPLICATIONS

Minor complications of nasogastric intubation include sinusitis, epistaxis, and sore throat. More serious complications include esophageal perforation, aspiration, pneumothorax, and, rarely, intracranial placement.^{9,10}



Securing the tube

REFERENCES

1. Sarr MG, Sanfey H, Cameron JL. Prospective, randomized trial of nasogastric suction in patients with acute pancreatitis. *Surgery* 1986;100:500-4.
2. Fuller RK, Loveland JP, Frankel MH. An evaluation of the efficacy of nasogastric suction treatment in alcoholic pancreatitis. *Am J Gastroenterol* 1981;75:349-53.
3. Naeije R, Salingret E, Clumeck N, De Troyer A, Devis G. Is nasogastric suction necessary in acute pancreatitis? *Br Med J* 1978;2:659-60.
4. Cuellar RE, Gavalier JS, Alexander JA, et al. Gastrointestinal tract hemorrhage: the value of a nasogastric aspirate. *Arch Intern Med* 1990;150:1381-4.
5. Witting MD, Magder L, Heins AE, Mattu A, Granja CA, Baumgarten M. Usefulness and validity of diagnostic nasogastric aspiration in patients without hematemesis. *Ann Emerg Med* 2004;43:525-32.
6. Gianelli Castiglione A, Bruzzone E, Burrello C, Pisano R, Ventura F, Canale M. Intracranial insertion of a nasogastric tube in a case of homicidal head trauma. *Am J Forensic Med Pathol* 1998;19:329-34.
7. Wrenn K. The lowly nasogastric tube: still appropriate after all these years (at times). *Am J Emerg Med* 1993;11:84-9.
8. Goff JS. Gastroesophageal varices: pathogenesis and therapy of acute bleeding. *Gastroenterol Clin North Am* 1993;22:779-800.
9. Sabga E, Dick A, Lertzman M, Tenenbein M. Direct administration of charcoal into the lung and pleural cavity. *Ann Emerg Med* 1997;30:695-7.
10. Thomas B, Cummin D, Falcone RE. Accidental pneumothorax from a nasogastric tube. *N Engl J Med* 1996;335:1325.

Copyright © 2006 Massachusetts Medical Society.