

Endotracheal Intubation

I. INDICATIONS, PATIENT EVALUATION, MANUAL MASK VENTILATION, PATIENT PREPARATION

See Chapter 1

II. EQUIPMENT

- A. Bag-mask-valve resuscitation unit with oxygen supplementation
- B. Topical anesthetic spray
- C. Medications as selected for analgesia/anesthesia, amnesia, and neuromuscular blockade
- D. Towel roll or pad for occipital elevation
- E. Pulse oximeter
- F. ECG monitor
- G. Automatic blood pressure device or personnel to provide frequent manual blood pressure monitoring
- H. Gloves, mask, eye protection
- I. Laryngoscope handle and blade(s) - usually sizes 3 and 4 curved and 2 and 3 straight
- J. Endotracheal tubes (usually 7.0- or 7.5-mm for adult women and 8.0-mm for adult men)
- K. Malleable stylet
- L. Yankauer and tracheal suction catheters, suction device
- M. Magill forceps
- N. 10-mL syringe to inflate cuff
- O. Water-soluble lubricant
- P. Qualitative CO₂ detector, CO₂ monitor, or esophageal detector device
- Q. Tape or tracheal tube stabilization device
- R. Resuscitation cart

III. ROUTE OF INTUBATION

- A. Orotracheal intubation via direct laryngoscopy
This route is generally favored in most circumstances, including when cervical spine injury is suspected. The assessment of the patient for degree of difficulty for oral intubation is discussed in Chapter 1.
- B. Blind nasotracheal intubation
The nasotracheal route using a blind approach in a spontaneously breathing patient may be favored by experienced operators in selected patients and situations. This technique has the advantage of allowing continued spontaneous ventilation and generally requires less sedation than direct laryngoscopy. It is more time-consuming than direct laryngoscopy and therefore has less utility in emergent intubation. Endotracheal tubes used for nasotracheal intubation are of smaller diameter than those used for orotracheal intubation. Nasotracheal intubation should be avoided if basilar skull fracture is suspected and in patients with coagulopathy.

For Pediatric Patients

The larynx of the infant or small child is cephalad, appearing anterior and making even routine intubation difficult. This anatomic difference between adults and children makes attempts at blind nasal intubation almost uniformly unsuccessful. Conventional wisdom suggests that attempts at blind nasal intubation be discouraged.

C. Cricothyrotomy

In some circumstances (e.g., trauma, severe neck or facial deformity, severe bleeding) a needle or surgical cricothyrotomy should be the primary method used to establish an airway. A needle cricothyrotomy with manual jet ventilation may be used as an adjunctive method to support oxygenation during other intubation attempts. Cricothyrotomy is discussed and described in Appendix 2.

IV. OROTRACHEAL INTUBATION

A. Preparation

1. Don gloves, mask, eye protection
2. Explain the procedure, if patient is conscious
3. Assure patent airway (Chapter 1)
4. Assure optimal oxygenation and ventilation (Chapter 1)
5. Assure IV access
6. Apply pulse oximeter, ECG, and blood pressure device
7. Assemble all equipment and ensure proper working order
8. Prepare the endotracheal tube
 - a. Check cuff integrity by inflating and fully deflating
 - b. Insert lightly lubricated stylet into endotracheal tube, bend to configuration predicted to assist glottic entry
 - c. Apply water-soluble lubricant to the cuff end of the tube
9. Connect laryngoscope blade to handle
 - a. Blade selection (operator's choice)
 1. Straight blade — used to elevate the epiglottis anteriorly
 2. Curved blade — inserted into the vallecula
 - b. Select blade length — #3 blade is proper unless patient's neck is very long
 - c. Assure that light from bulb is bright
10. Place pad or towel under occiput if cervical spine injury not suspected
11. Topically anesthetize the patient's oropharynx
12. Preoxygenate with 100% oxygen for 2 to 3 minutes or using 3 to 4 vital capacity breaths if time permits
13. As necessary, proceed with sedation and neuromuscular blockade (Chapter 1)

B. TECHNIQUE

1. The operator stands at the head of the bed, and the bed is raised to a position of comfort for the operator. The head of the bed may be flat or raised slightly per operator preference.

2. When no cervical injury is suspected, a small pad is placed under the occiput (the “sniffing” position) and the neck is gently extended (Fig. A1-1). When cervical spine injury is possible, these steps are omitted and the neck is stabilized by an assistant (as described in Chapter 1) and the anterior portion of the cervical collar is removed.

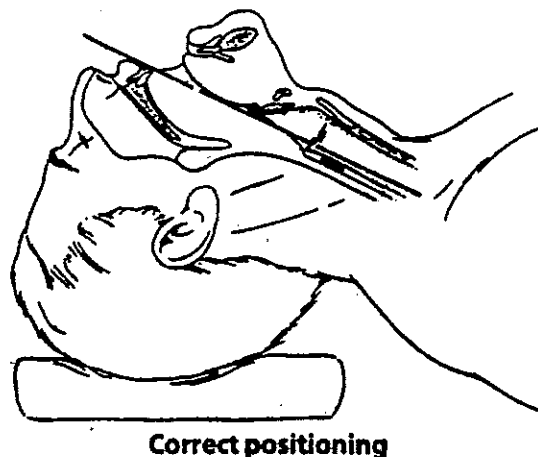


Figure A1-1. To visualize the trachea, the axial planes of the oral, pharyngeal, and tracheal axes must be aligned. This alignment can be accomplished by flexing the neck at the level of the cervical spine and extending the head at the atlanto-occipital joint. Illustration © by Robert Margulies and reproduced with permission from the artist and *The Journal of Critical Illness*.

3. Regardless of the operator's dominant hand in other contexts, the laryngoscope is always held in the left hand.
4. Cricoid pressure should be gently but firmly applied by an assistant as soon as consciousness is lost and should be sustained until endotracheal tube placement is confirmed and the cuff inflated.
5. Mouth opening in the sedated/relaxed patient may be assisted by a cross-finger technique wherein the thumb of the right hand is placed on the front lower teeth of the mandible and the first finger on the front upper teeth (maxilla). The mouth is gently opened by a “reverse scissor” movement of the fingers and the laryngoscope is introduced into the mouth.
6. Insert tip of laryngoscope blade into the right side of the patient's mouth (Fig. A1-2); advance the blade to the base of the tongue.
7. Sweep the tongue to left; proper tongue control is key to laryngeal visualization.
8. Gently advance the blade further to its proper position. A straight blade is placed beneath the epiglottis; a curved blade is placed into the vallecula above the epiglottis.
9. Caution! Traction should be applied only along the long axis of the laryngoscope handle as the laryngoscope lifts the tongue upward away from the larynx, revealing the glottic opening. A rocking or rotating motion of the blade and handle may damage teeth, gingiva, or lips. The base of the laryngoscope blade should never contact the upper teeth!
10. Visualize the vocal cords and glottic opening.

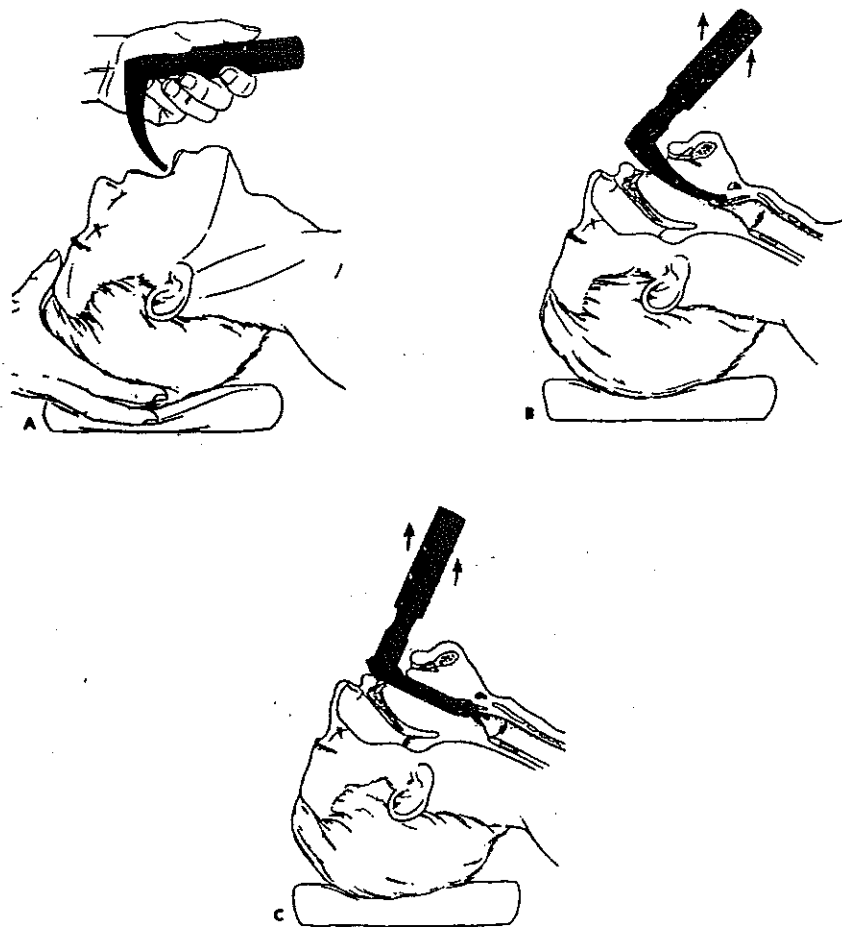
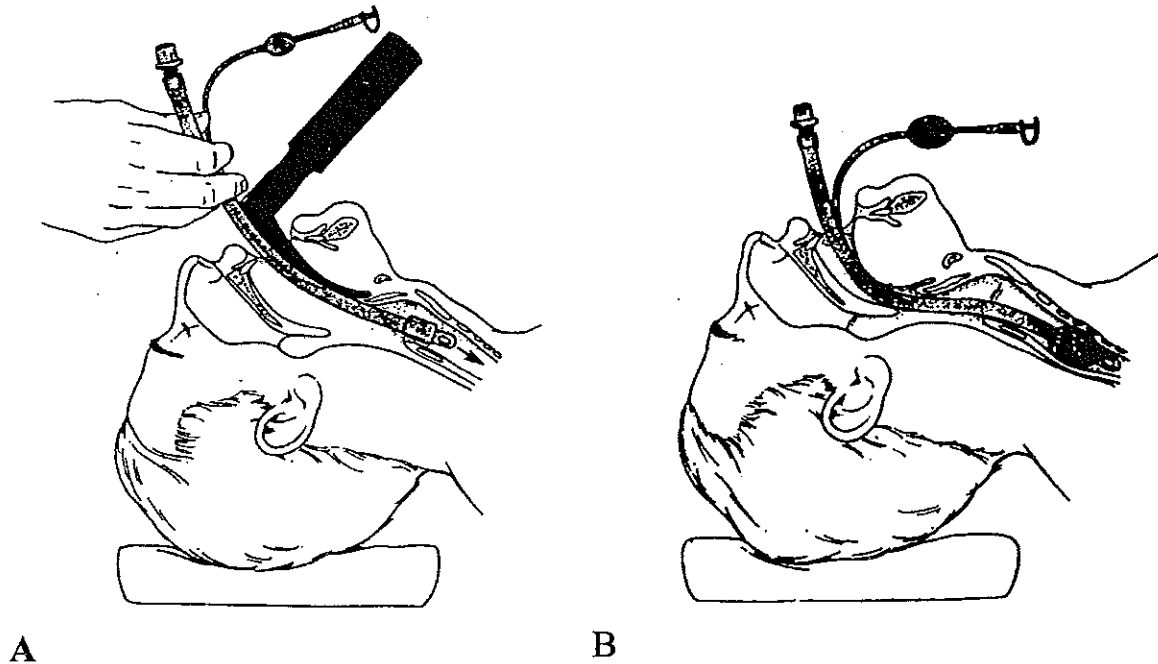


Figure A1-2. (A) The blade of the laryngoscope is inserted into the patient's mouth and pushes the tongue to the left. (B) The straight blade is inserted beneath the epiglottis, and (C) the curved blade follows the base of the tongue and is inserted into the vallecula. Illustration © by Robert Margulies and reproduced with permission from the artist and *The Journal of Critical Illness*.

11. If the vocal cords and glottis cannot be visualized, it may be helpful for an assistant to grasp the thyroid cartilage between the thumb and index finger and exert pressure in the following sequence: Pressure is applied backward against the cervical vertebrae and then in an upward direction to shift the larynx superiorly. Additional pressure is applied to shift the thyroid cartilage no more than 2 cm to the right side of the patient's neck. This procedure can be remembered by the acronym BURP (backward, upward, and rightward pressure on the thyroid cartilage).
12. Gently insert the endotracheal tube through the vocal cords (Fig. A1-3), holding the tube/stylet with the right hand. The stylet, if angled, may interfere with passage of the tube into the trachea. If resistance is encountered as the tube is advanced, consider having an assistant remove the stylet while the operator holds the endotracheal tube firmly in the glottic opening.

13. Carefully remove stylet and laryngoscope (Fig. A1-3). The operator must continue to firmly hold the endotracheal tube; position the tube such that the external centimeter length markers on the tube show 21 cm (female) or 23 cm (male) adjacent to the front teeth.
14. Inflate cuff.



*Figure A1-3. (A) The endotracheal tube is inserted through the vocal cords until the distal end rests approximately 2 to 3 cm above the carina. (B) Once the endotracheal tube is in proper position, the laryngoscope and stylet are removed and the cuff is inflated. Illustration © by Robert Margulies and reproduced with permission from the artist and *The Journal of Critical Illness*.*

15. To ensure proper position of the tube:
 - a. Inspect and auscultate chest to assure equal bilateral gas entry
 - b. Use qualitative CO₂ detector or monitor or esophageal detector device. Lack of color change with a qualitative CO₂ detector or low exhaled CO₂ may occur with a correctly placed tracheal tube in the patient with poor pulmonary perfusion.
 - c. Observe for condensation in the endotracheal tube during exhalation
 - d. Listen for breath sounds through the endotracheal tube as the patient is breathing spontaneously.
 - e. Obtain chest radiograph (tube tip 2 to 3 cm above carina)
16. Secure endotracheal tube with tape or endotracheal tube stabilization device

VI. BLIND NASOTRACHEAL INTUBATION

A. Preparation

1. See steps 1-8, Preparation for orotracheal intubation.
2. Position the patient's head on a small towel with the neck in a slightly extended position.
3. Preoxygenate with 100% oxygen for 2 to 3 minutes or using 3 to 4 vital capacity breaths if time permits.
4. Topically anesthetize the nasal passages and pharynx and lubricate the nasal passages.

B. Technique

1. The operator stands at the head of the bed, and the bed is raised to a position of comfort for the operator. The head of the bed may be flat or raised slightly per operator preference. The patient should have spontaneous ventilations and an adequate tidal volume.
2. Use the larger nare if there is significant deviation of the nasal septum.
3. Gently insert a well-lubricated endotracheal tube without the stylet inserted through the nasal passage into the posterior oropharynx.
4. Oxygen may be administered by face mask/blowby or by intermittently connecting the oxygen source to the endotracheal tube.
5. Inspect the oropharynx to assure that the endotracheal tube is midline.
6. The amount of air movement at the endotracheal tube connector is assessed by either listening to air movement through the tube, using a specially designed "whistle," or using an exhaled CO₂ monitor.
7. Slowly advance the endotracheal tube. Feel and listen at the connector end of the endotracheal tube for air movement. Continue to advance the tube if air movement increases through the tube. If air movement decreases, withdraw the endotracheal tube until air movement resumes, and readvance after repositioning the head.
8. Advancing the tube through the glottis is usually easier during inspiration.
9. The operator must continue to firmly hold the endotracheal tube; position the tube such that the external centimeter length markers on the tube show approximately 24 cm (female) or 26 cm (male) adjacent to the nare.
10. Inflate cuff.
11. To ensure proper position of the tube
 - a. Inspect and auscultate chest to assure equal bilateral gas entry
 - b. Use qualitative CO₂ detector, or monitor or esophageal detector device. Lack of color change with a qualitative CO₂ detector or low exhaled CO₂ may occur with a correctly placed endotracheal tube in the patient with poor pulmonary perfusion.
 - c. Observe for condensation in the endotracheal tube during exhalation.
 - d. Listen for breath sounds through the endotracheal tube as the patient is breathing spontaneously
 - e. Obtain chest radiograph (tube tip 2 to 3 cm above carina)
12. Secure endotracheal tube with tape or endotracheal tube stabilization device

VI. PEDIATRIC CONSIDERATIONS

A. Anatomic differences between adults and children

1. The larynx is more cephalad in infants than in adults, making it appear more anterior and resulting in a more difficult visualization during laryngoscopy.

2. Cricoid pressure is valuable during laryngoscopy because of the position of the larynx and assists in preventing aspiration.
 3. In young children, the narrowest part of the airway is at the level of the cricoid cartilage, not at the larynx, making an anatomic “cuff” below the vocal cords.
 4. In general, the diameter of the small finger approximates the properly sized endotracheal tube. A full-term neonate can accept a 3.5-mm inner-diameter tube.
 5. Cuffed tubes are therefore usually limited to use in children >8 years old (endotracheal tube size >6.0-mm internal diameter); uncuffed tubes are generally used in younger children.
- B. Technique differences between adults and children
1. Head position: a towel roll under the head is often needed in adults to achieve the sniffing position; a shoulder roll is usually needed to achieve this position in infants.
 2. Laryngoscope blade selection: choice of a straight or curved blade is individual; however, most clinicians do not use curved blades in infants. A common mistake in intubating a child is choosing a blade that is too small. The blade must be long enough to reach the epiglottis.
 3. Proper depth of insertion in centimeters can be estimated by multiplying the internal diameter of the endotracheal tube by 3 (e.g., internal diameter = 4.0; depth of insertion = $4.0 \times 3 = 12.0$ cm).
 4. Appropriately sized equipment (e.g., face mask, laryngoscope, endotracheal tube, suction catheter) should be used.

VI. PRECAUTIONS/COMPLICATIONS

- A. Hypoxia, hypercapnia during procedure
- B. Cardiovascular compromise during and immediately after procedure
- C. Damaged teeth, lips, gingiva
- D. Malpositioned tube (esophagus, right mainstem bronchus)
- E. Pharyngeal, laryngeal, tracheal damage
- F. Gastric distension and aspiration of gastric contents
- G. Bronchospasm

SUGGESTED READINGS

1. Balk RA: The technique of orotracheal intubation. *J Crit Illness* 1997; 12:316
2. Gerardi MJ, Sacchetti AD, Cantor RM, et al: Rapid-sequence intubation of the pediatric patient. Pediatric Emergency Medicine Committee of the American College of Emergency Physicians. *Ann Emerg Med* 1996; 28:55
3. Knill RL: Difficult laryngoscopy made easy with a “BURP.” *Can J Anaesth* 1993;40:279.
4. Popovich MJ, Hoffman WD: Endotracheal intubation. *In: Current Therapy in Critical Care Medicine*. Parrillo JE (Ed). St. Louis, CV Mosby, 1997, p 8
5. Tobias JD: Airway management for pediatric emergencies. *Pediatr Annals* 1996; 25:317